

Case report of nasopharyngeal rhabdomyosarcoma causing obstructive sleep apnoea

A 4-year-old girl presented in acute airway distress. She had previously seen otolaryngology, a presumptive diagnosis of obstructive sleep apnoea (OSA) was made on the basis of symptoms and the presence of large tonsils, and adenotonsillectomy recommended. However, healthcare rationing resulted in delay to surgery.

Acute examination of the airway under anaesthetic demonstrated a firm, lobulated mass on the nasopharyngeal surface of the uvula extending cranially to skull base and laterally to the pharyngeal walls. Extensive biopsies were taken (Fig. 1) and the tumour debulked to restore airway patency.

Post-operatively, acute respiratory distress resolved. Care was transferred to paediatric oncology with a presumptive diagnosis of malignancy.

Histopathology confirmed botryoid rhabdomyosarcoma. Magnetic resonance imaging showed extensive residual disease in the nasopharynx, an enlarged cervical lymph node (Fig. 2) with final staging stage 1, group III (T2b,Nx,M0). Chemotherapy commenced, no complications were reported and imaging at 9 months showed that disease was clear.

Children with OSA commonly present with snoring generated from upper airway airflow limitation. Typically, airflow limitation originates in the pharynx (tonsils and adenoids), less commonly in

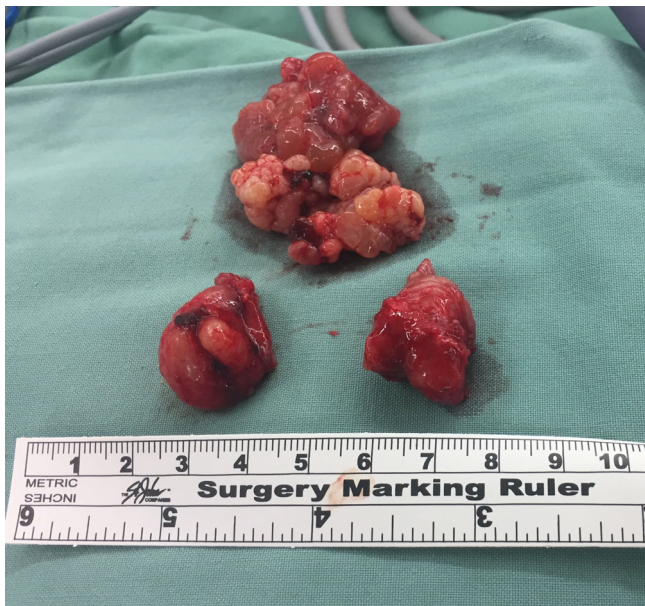

Fig. 1. Nasopharyngeal mass associated with adenoid, as well as bilateral tonsils.

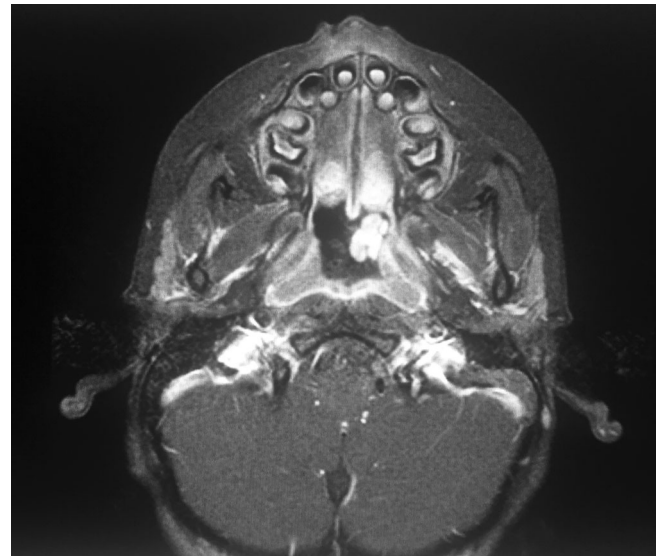


Fig. 2. Post-operative axial magnetic resonance imaging demonstrating extensive soft-tissue density mass arising in the nasopharynx.

other sites (nose, base of tongue or larynx). Tumours in the upper airway¹⁻⁷ cause OSA by the reduction of lumen of the mobile-walled airway² coupled with loss of muscle tone in sleep.

This is the first reported case of pharyngeal rhabdomyosarcoma presenting as OSA. A single other case links OSA to rhabdomyosarcoma, that one nasal.⁸

Early diagnosis and treatment is imperative, so tumours must be considered as a cause of OSA. Generally, rapid progression of symptoms of snoring or apnoea in children should prompt the clinician to consider other diagnoses, such as space-occupying lesions. This is particularly important where examination findings, such as small tonsils and adenoids, do not support the more common diagnosis of OSA.

Best management is multidisciplinary and requires specialized care and communication.

References

1. Leong P, Kleid S, Mansfield D. Retropharyngeal lipoma causing obstructive sleep apnoea. *Respirol. Case Rep.* 2017; 5: e00251.
2. Aydin U, Karakoc O, Binar M, Arslan F, Gerek M. Intraoral excision of a huge retropharyngeal lipoma causing dysphagia and obstructive sleep apnea. *Braz. J. Otorhinolaryngol.* 2016; <http://dx.doi.org/10.1016/j.bjorl.2016.10.011>.

3. Cirocco A, González F, Sáenz AM, Jiménez C, Sardi JR, Oscar RF. Embryonal rhabdomyosarcoma of the tongue. *Pediatr. Dermatol.* 2005; **22**: 218–21.
4. Zhu SJ, Wang QY, Zhou SH, Bao YY, Wang SQ. Obstructive sleep apnea syndrome caused by uncommon tumours of the upper aerodigestive tract. *Int. J. Clin. Exp. Pathol.* 2014; **7**: 6686–93.
5. Gómez-Merino E, Arriero JM, Chiner E, Signes-Costa J, Marco J. Obstructive sleep apnea syndrome as first manifestation of pharyngeal non-Hodgkin's lymphoma. *Respiration* 2003; **70**: 107–9.
6. Casale M, Salvinelli F, Mallio CA *et al.* Upper airway study should always come before any sleep study in OSAS evaluation: a giant parapharyngeal lipoma behind OSAS. *Eur. Rev. Med. Pharmacol. Sci.* 2012; **16**: 106–9.
7. Smadi T, Raza MA, Woodson BT, Franco RA. Obstructive sleep apnea caused by carotid body tumour: case report. *J. Clin. Sleep Med.* 2007; **3**: 517–8.
8. Caversaccio M, Stauffer E. Botryoid rhabdomyosarcoma of the nose: pitfalls of pathology. *ORL J. Otorhinolaryngol Relat. Spec.* 2001; **63**: 178–82.

Rachelle L. Love,* FRACS 

Stuart G. MacKay,† FRACS

**Canterbury District Health Board, Canterbury, New Zealand and*
†*Illawarra Head and Neck Clinic, Wollongong, New South Wales,*
Australia

This study was presented at the 2018 New Zealand Society of
Otolaryngology, Head and Neck Surgery Meeting.

doi: 10.1111/ans.15369