

Implantation of the Nyxoah Bilateral Hypoglossal Nerve Stimulator for Obstructive Sleep Apnea

Richard Lewis, MBBS; Boris Pételle, MBBS; Matthew C. Campbell, MBBS;
Stuart MacKay, BSc (Med), MBBS; Carsten Palme, MBBS; Guillaume Raux, PhD; J. Ulrich Sommer, MD;
Joachim T. Maurer, MD

Objectives: This report describes the surgical implantation of a novel bilateral hypoglossal nerve stimulator (Genio system[®], Nyxoah S.A., Belgium) and the successful treatment of a patient with moderate obstructive sleep apnea (OSA).

Study Design: Surgical technique description and case study report.

Methods: The bilateral implantable stimulator (IS) simultaneously stimulates both genioglossus (GG) muscles to reduce airway obstruction. At night, patients wear an activation chip under their chin that wirelessly transmits energy to the implant and enables the nerve stimulation. Surgical implantation of the IS is performed under general anesthesia by making a small incision above the hyoid bone and dissecting through the platysma, mylohyoid, and geniohyoid muscles to the GG muscle. The hypoglossal nerve branches are then identified, followed by suturing the IS in place. The system was evaluated in an otherwise healthy, 60-year-old woman with moderate OSA (apnea hypopnea index (AHI): 25/hr, nadir O₂ saturation: 78%). Appropriate stimulation settings were determined at 2-, 3-, and 6-months post implantation during polysomnography (PSG) and changes in apnea and hypopnea events and oxygen desaturation recorded.

Results: The surgery was well tolerated by the patient with an uneventful recovery. The PSG at 6 months showed that AHI per hour, obstructive apnea events per hour, hypopnea events per hour, and oxygen desaturation index have been reduced by 88%, 92%, 88%, and 97%, respectively, and nadir O₂ saturation improved to 91%.

Conclusions: The absence of complications and considerable reduction of apnea and hypopnea events in this case study help demonstrate the potential safety and efficacy of the bilateral hypoglossal nerve stimulator.

Key Words: Obstructive sleep apnea, bilateral, hypoglossal nerve stimulation, neuromodulation.

Level of Evidence: 4

INTRODUCTION

Obstructive sleep apnea (OSA) is a common and heterogeneous condition characterized by repeated partial or complete obstructions of the pharyngeal airway during sleep. In the majority of patients, there is an anatomical predisposition to the disorder.^{1,2} Compounding this may be abnormalities in ventilatory control (such as high loop gain), and/or a low arousal threshold during sleep. The pharyngeal muscles respond to inputs from mechanoreceptors in the airway, as well as changes in oxygen and CO₂ levels in the blood. The genioglossus (GG) is the major dilator of the pharyngeal

airway.³ Failure of the upper airway dilator muscles to respond appropriately to airflow limitation and changes in CO₂ and O₂ levels is known to contribute to OSA.

Hypoglossal nerve stimulation as a means to dilate the pharyngeal airway was first described in a feline model⁴ and since then, a few devices (Apnex, Inspire, ImThera) have been developed to stimulate the hypoglossal nerve unilaterally in patients with OSA. The Inspire Medical device has been in use for over 7 years and is approved for use in both Europe and North America⁵ with the results from the STAR study⁶ published in 2014. While the efficacy of hypoglossal nerve stimulation has been proven over time, potential difficulties with existing systems arise (lead tunneling from the submandibular area to the chest to be connected to a “pace-maker like” system, unilateral nerve stimulation, multiple incision sites). The Genio system avoid these issues by offering bilateral stimulation of the hypoglossal nerve branches that may lead to potentially greater airway opening combined with only one incision in the chin area, no tunneling, and no long wires or battery. We describe the surgical implantation of the Genio nerve stimulator and its application in an otherwise healthy patient with moderate OSA.

This is an open access article under the terms of the Creative Commons Attribution-NonCommercial-NoDerivs License, which permits use and distribution in any medium, provided the original work is properly cited, the use is non-commercial and no modifications or adaptations are made.

From the Hollywood Private Hospital (R.L.), Perth, Western Australia, Australia; Hôpital Tenon AP-HP (B.P.), Paris, France; Institute for Breathing and Sleep, Austin Health (M.C.C.), Melbourne, Victoria, Australia; Illawarra ENT Head and Neck Clinic (S.M.), Wollongong, New South Wales, Australia; Westmead Private Hospital (C.P.), Sydney, New South Wales, Australia; Nyxoah S.A. (G.R.), Mont-Saint-Guibert, Belgium; Helios University Hospital Wuppertal (J.U.S.), University Witten/Herdecke - Wuppertal, Germany; Division Of Sleep Medicine, Department of ORL-HNS (J.T.M.), University Medicine Mannheim.

Editor's Note: This Manuscript was accepted for publication on August 25, 2019.

Conflict of Interest: None to declare.

Funding: This study was funded by Nyxoah S.A., Belgium.

Send correspondence to Guillaume Raux, Rue Edouard Belin 12, 1435 Mont-Saint-Guibert, Belgium. E-mail: guillaume.raux@nyxoah.com

DOI: 10.1002/liv.2312

MATERIALS AND METHODS

The Device

The Genio implantable stimulator (IS) consists of two sets of paired stimulating electrodes and a receiving antenna in the center

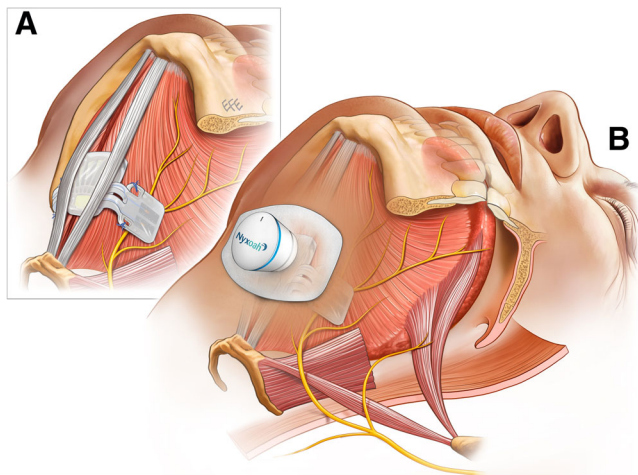


Fig. 1. The Genio Neurostimulation system (Nyxoah SA, Belgium) for the treatment of obstructive sleep apnea. (A) The implantable stimulator (IS) has two sets of electrodes which are positioned over the medial branches to stimulate the hypoglossal nerve. (B) At night, the patient connects the activation chip which stores the stimulation settings, on a disposable adhesive patch under the chin which transmits energy wirelessly to the IS to stimulate muscle contraction. The images are for illustrational purposes only and it should be appreciated that surgical anatomy might differ between patients thereby requiring adjusted placement over the respective area of the hypoglossal nerve.

encased in a silicon envelope to protect the antenna and circuitry (Fig. 1A). The two sets of electrodes are located on two flexible legs to accommodate movement of the GG muscles and allow for variable neural anatomy. The IS design allows positioning over both GG muscles with the stimulating paddle electrodes facing the medial branches of the hypoglossal nerve on each muscle. The IS is the only implantable component of the Genio system and is a passive device that does not contain a battery. As shown in Figure 1B, the IS is activated by wireless energy transmission from an activation chip (AC), which the patient wears when they are asleep, attaching it to the adhesive disposable patch (DP). Each morning, the patient removes the AC from the DP, discards the DP, and recharges the AC. The storage memory of the AC contains the patient-specific stimulation parameters which are programmed by the treating physician. The external stimulator (ES, not shown here) contains an electrical pulse generator and is only used during surgery to activate the implant and confirm the optimal IS placement.

Patient Setup

As shown in Figure 2, under general anesthesia with nasotracheal intubation, the patient was placed in a supine position and the neck extended with a shoulder roll. Four electrodes connected to the nerve integrity monitoring system (NIM 3.0, Medtronic) were inserted into the tongue to locate the medial branches of the hypoglossal nerve and to verify proper muscle contraction: one set of electrodes in each GG muscle, and the other one in each styloglossus (SG) muscle.⁷ The mouth was kept open with a roll of gauze inserted laterally between the teeth so that tongue movement can be observed during stimulation and a video nasal endoscope inserted to visualize the epiglottis and tongue base.

Implantation Technique

Following 2 g intravenous Cefazolin, a 6 cm transverse incision was made midway between the mentum and the hyoid

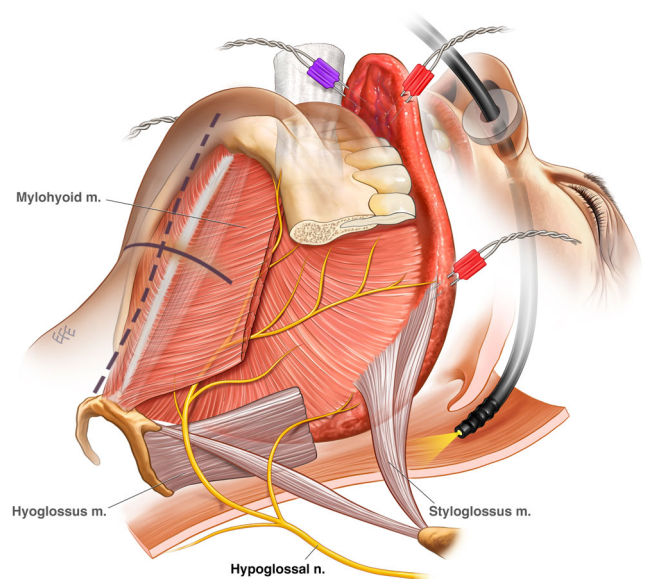


Fig. 2. Patient setup and location of incision for implant: Under general anesthesia, the patient is placed supine with a nasal endoscope to visualize airway opening and connected to the nerve integrity monitoring system to locate the medial branches of the hypoglossal nerve.

bone. Subplatysmal flaps were raised up to the mentum and down to the thyroid notch. The mylohyoid muscle was divided in the midline. Once the mylohyoid was divided, the vertical fibers of the geniohyoid (GH) muscles were identified. The GH muscles were then separated and retracted. The lateral border of the GG was then identified, and the fat lateral to it was carefully explored to find the hypoglossal nerve which passes supero-medially to intersect the GG at an angle of approximately 60°. The mylohyoid muscle was divided in the midline (Fig. 3).⁸

The bipolar stimulator probe of the NIM was then used to assist in locating the nerve and was initially set at 0.5–1 mA. The nerve was then dissected cleanly on its superior aspect, and a deep pocket made superior to the nerve to fit the legs of the IS in without any external force. Once the nerve was exposed on its superior aspect, and the pocket made, the NIM stimulator was used to confirm electrode position with stimulus reduced to 0.1 mA. This was to avoid retrograde stimulation of the hypoglossal nerve, which could cause spurious stimulation of the SG electrode. The process was then repeated for the right nerve.

The implant was then placed into position, with one leg inserted into its pocket and ensuring that the nerve passed across both electrodes. When the positioning was satisfactory, an ES was placed flush against the device antenna to activate the IS and the stimulation effect tested. If the IS is positioned optimally, the NIM monitor should display high potentials in the GG electrode with a low reading in the SG electrode. Upon satisfactory readings combined with a strong tongue contraction, the leg of the IS was fixed in place on the GG with 2 × 2/0 Ethibond sutures (Ethicon, Inc., NJ) placed using nontoothed forceps through the dedicated suture holes located on each device leg. The same process was repeated for the other side.

To confirm the IS was still in the correct position after suturing, it was then tested with the AC. The skin edges were temporarily closed with a single suture and covered with a clear sterile plastic sheet and the AC/DP placed on top and activated with the responses on the NIM monitor and

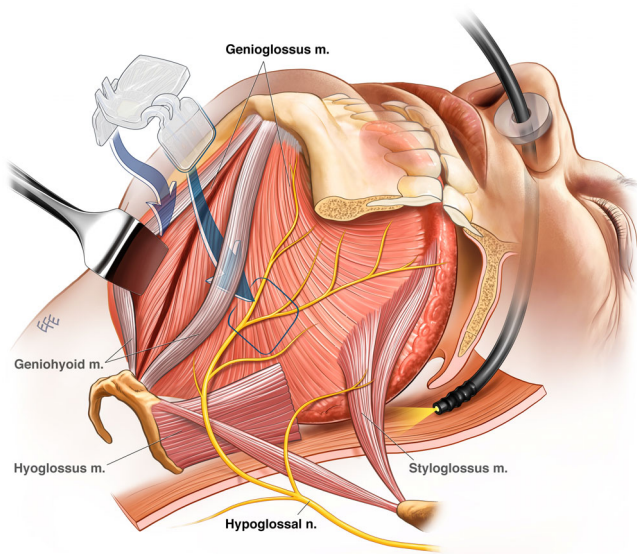


Fig. 3. Surgical implantation of the hypoglossal nerve stimulator. Cautery is used to dissect vertically in the midline through fat down to the mylohyoid muscle and geniohyoid (GH) muscles. After separation of the GH muscles, the genioglossus (GG) muscles are identified and the fat lateral to it is carefully explored to find the hypoglossal nerve which passes supero-medially to intersect the GG with the stimulator probe of the nerve integrity monitoring then used to assist in location of the nerve. The nerve is dissected cleanly on its superior aspect, and a deep pocket made superior to the nerve to fit the legs of the IS. Dissection is carried out to look for a branch to this muscle which will head superiorly and gently dissected away from the medial continuation of the hypoglossal nerve, the pocket is then made medial to the branch and illustration showing the relative placement of the IS on the hypoglossal nerve. The GH muscles are sutured together, then the mylohyoid muscle repaired, and the platysma and skin closed.

movement of the tongue, epiglottis and palate observed with the endoscope. Once the responses were satisfactory, the neck was reopened, the muscles reapproximated and closed with sutures, and the skin closed. A waterproof dressing was applied. One final check of the implant was performed with the AC/DP, and the endoscope used to visualize the dynamic changes in the airway. The patient was then extubated, transferred to the recovery room, and then the ward. The total operating time was approximately 90 minutes.

Postoperative Management

Analgesic requirement was minimal, with pain scores assessed at 2/10. Free oral intake was allowed. The patient was reviewed the next morning and discharged home. They were instructed to keep the waterproof dressing on for 5 days then remove it, and a review was conducted 7 days following surgery.

Device Activation and Titration

At 6 weeks post surgery, the patient was booked in to activate the device. Initially, a low stimulus setting was programmed to help the patient acclimate to the sensation of tongue stimulation. Two weeks later, the first titration polysomnography (PSG) was undertaken, during which the patient stimulation optimal parameters were defined. The following parameters are programmable: pulse length, pulse frequency, train length, train interval, and pulse amplitude. The stimulation is neither phasic nor tonic,

but instead it is cyclical (rolling window approach where the length of the ON/OFF stimulation period is programmed). Our approach is neither to monitor the respiration (no sensing lead) nor to stimulate continuously on a predetermined set of electrodes for a set duration of time. Instead, Nyxoah's approach is to use a pseudo-continuous stimulation to prevent muscle fatigue while delivering safe hypoglossal nerve (HGN) stimulation. The sleep specialist can preprogram the total amount of the stimulation window and determine percentage of ON time within this window. The stimulation window will then repeat itself until the therapy is turned OFF.

RESULTS

Case Report

A 60-year-old female with moderate OSA (AHI: 24.6, oxygen desaturation index (ODI) 3%: 19.5) was intolerant of nasal continuous positive airway pressure (CPAP). She was tired and sleepy, with an Epworth Sleepiness Score of 14. Her other medical problems included asthma and osteoporosis. Examination revealed a thin woman (BMI 20.7) with a class 2 malocclusion and overjet, and a mild septal deviation. She had a Friedman grade 2 tongue position, and no tonsils. Endoscopic examination revealed antero-posterior (AP) narrowing of the retro-palatal airway, and to a lesser degree the retrolingual airway. There was grade 2 lingual tonsillar hypertrophy.

She was screened for the Nyxoah Hypoglossal Nerve Stimulator and successfully passed the screening. Her drug-induced sleep endoscopy showed AP retropalatal obstruction, and AP retrolingual obstruction. She underwent implantation in March 2018. She was discharged the morning after surgery and had an uneventful recovery. Her baseline screening PSG and 2-, 3-, and 6-month titration PSG figures are depicted in Table I. Her comparison of baseline and 3-month titration data shown in Figure 4 demonstrates excellent control of her OSA in the supine position. The patient reported reduced daytime sleepiness and her Epworth Sleepiness Scale score was reduced from 16 at screening to 1 at 6 months while her Functional Outcomes of Sleep Questionnaire-10 score increased from 16 to 20 at these timepoints. The patient was last seen in May 2019 for a follow-up visit and reported to still not have daytime sleepiness anymore and as well as continuing to wake up feeling refreshed.

TABLE I.
Apnea and Oxygen Desaturation Indexes at Baseline and 2-, 3-, and 6-months Titration Visits.

	Baseline	Month 2	Month 3	Month 6
AHI	24.6	1.3	2.5	3.0
AI	3.7	0.3	0.5	0.3
HI	20.9	1.0	2.1	2.7
ODI (3%)	19.5	0.6	2.2	2.2
ODI (4%)	11.8	0.5	1.7	0.1
Nadir O ₂ saturation (%)	78.0	89.0	89.0	91.0
Supine AHI	36.9	2.3	3.3	0.9
Nonsupine AHI	20.5	0.9	1.5	2.7

AHI = Apnea Hypopnea Index; AI = Apnea Index; HI = Hypopnea Index; ODI = Oxygen Desaturation Index.

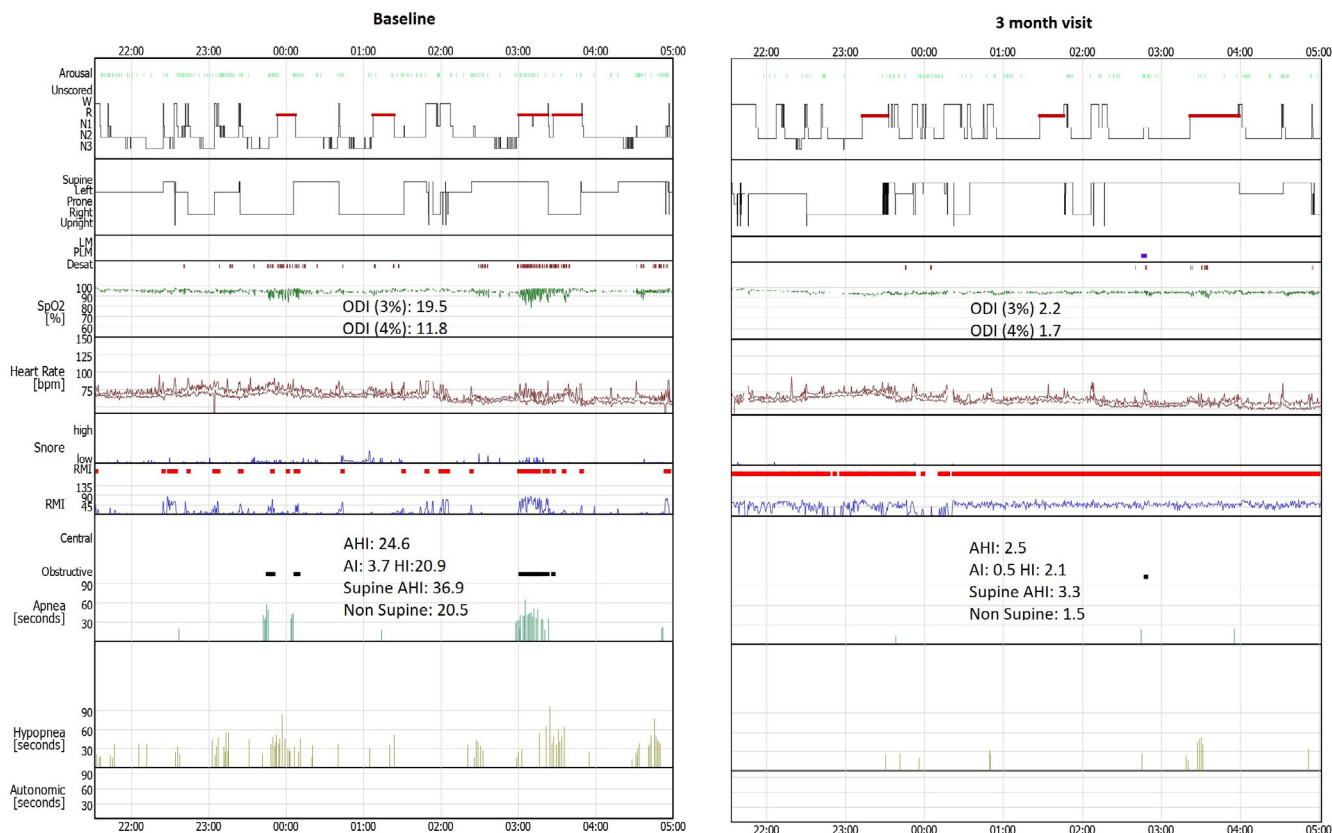


Fig. 4. Comparison of hypnograms from the implanted patient at baseline and at 3 months titration visit. LM = Limb Movement; PLM = Periodic Limb Movement; RMI = Respiratory Mechanic Instability.

DISCUSSION

The consequences of OSA range from disruptive to potentially fatal^{9,10} and although CPAP is the gold standard for treatment with proven efficacy,¹¹ long-term compliance remains variable¹² and more effective treatments are needed. Over the past 15 years, hypoglossal nerve stimulation has emerged as a treatment for OSA^{3,13} with the concept recently commercialized.^{6,14,15} However, currently commercially available devices involve relatively invasive implantation, and comprise a cuff electrode that is wrapped around the hypoglossal nerve. Moreover, those technologies require additional incision sites for implanting sensing/stimulating leads and a pulse generator. Implantation of the Genio is minimally invasive with only a single incision site required.

There are several important considerations which have been garnered from the experience gained in developing the surgical technique described here. Patient setup (Fig. 2) to visualize the effect of stimulation on the tongue and airway using endoscopy as described is critical to evaluating if placement of the IS on the hypoglossal nerve branches is optimal. Preparation of the pocket above the hypoglossal nerve is critical for success and we have found that exposing the nerve as close to the GG as possible will reduce the likelihood of any retrusor branches being stimulated. If nerve branches are seen, they should be stimulated with the NIM to determine whether or not they are retrusor branches. If significant stimulation of the SG occurs, then careful dissection needs to be carried out to

look for a branch to this muscle which will head superiorly. If found, it should be gently dissected away from the medial continuation of the hypoglossal nerve, and the pocket made medial to the branch. Ensuring the distance between the antenna of the IS and skin surface is less than 3.5 cm is recommended for optimal performance of the IS when activated. Hence, some fat can be removed either superficially or deep to the platysma. If there has been significant fat removal, a small suction or Penrose drain may be used. Finally, when suturing the IS, the suture should initially be passed through the device first, and then through the soft tissue before tying the knots. Small bites of the underlying muscle are taken with the needle. A small right-angle clamp can be used to support the device on its deep surface which makes it easier to push the suture needle through the suture holes.

The safety and efficacy and of the IS were demonstrated in a 60-year-old woman with moderate OSA. There were no complications, and an uneventful recovery and activation of the IS at 2 months postsurgery resulted in considerable reduction in AHI and ODI. The single case study serves to describe the surgical protocol for a prospective study currently being completed.

CONCLUSION

The implantation procedure of the Genio bilateral hypoglossal nerve stimulator is relatively noninvasive, involving dissection to the GG and the placement of the

electrodes of the IS on both the left and right hypoglossal nerve branches. The implantation was safe and its therapeutic benefit demonstrated in reducing measures of sleep apnea in a single case study. The technology seems to be promising, and additional trials will be initiated to confirm positive outcomes of the BLAST OSA study.

BIBLIOGRAPHY

1. Neelapu BC, Kharbanda OP, Sardana HK, et al. Craniofacial and upper airway morphology in adult obstructive sleep apnea patients: a systematic review and meta-analysis of cephalometric studies. *Sleep Med Rev* 2017; 31:79–90.
2. Eckert DJ, White DP, Jordan AS, Malhotra A, Wellman A. Defining phenotypic causes of obstructive sleep apnea. Identification of novel therapeutic targets. *Am J Respir Crit Care Med* 2013;188(8):996–1004.
3. Schwartz AR, Bennett ML, Smith PL, et al. Therapeutic electrical stimulation of the hypoglossal nerve in obstructive sleep apnea. *Arch Otolaryngol Head Neck Surg* 2001;127(10):1216–1223.
4. Schwartz AR, Thut DC, Russ B, et al. Effect of electrical stimulation of the hypoglossal nerve on airflow mechanics in the isolated upper airway. *Am Rev Respir Dis* 1993;147:1144–1144.
5. Woodson BT, Strohl KP, Soose RJ, et al. Upper airway stimulation for obstructive sleep apnea: 5-year outcomes. *Otolaryngol Head Neck Surg* 2018;159(1):194–202.
6. Strollo PJ Jr, Soose RJ, Maurer JT, et al. Upper-airway stimulation for obstructive sleep apnea. *N Engl J Med* 2014;370(2):139–149.
7. Heiser C, Hofauer B, Lozier L, Woodson BT, Stark T. Nerve monitoring-guided selective hypoglossal nerve stimulation in obstructive sleep apnea patients. *Laryngoscope* 2016;126(12):2852–2858.
8. Bassiri Gharb B, Tadisina KK, Rampazzo A, et al. Microsurgical anatomy of the terminal hypoglossal nerve relevant for neurostimulation in obstructive sleep apnea. *Neuromodulation* 2015;18(8):721–728.
9. Kushida CA. *Obstructive Sleep Apnea: Pathophysiology, Comorbidities and Consequences: Pathophysiology, Comorbidities, and Consequences*: Informa Health Care; CRC Press, 2007.
10. Young T, Peppard PE, Gottlieb DJ. Epidemiology of obstructive sleep apnea: a population health perspective. *Am J Respir Crit Care Med* 2002;165(9): 1217–1239.
11. Koseoglu S, Ikinciogullari A, Cetin MA, Saygi Uysal G, Kum RO, Arli B. The clinical efficiency of positive airway pressure treatment. *Scientific World Journal* 2013;2013:245476.
12. Weaver TE, Grunstein RR. Adherence to continuous positive airway pressure therapy: the challenge to effective treatment. *Proc Am Thorac Soc* 2008;5(2):173–178.
13. Kezirian EJ, Boudewyns A, Eisele DW, et al. Electrical stimulation of the hypoglossal nerve in the treatment of obstructive sleep apnea. *Sleep Med Rev* 2010;14(5):299–305.
14. Oliven A, O’Hearn DJ, Boudewyns A, et al. Upper airway response to electrical stimulation of the genioglossus in obstructive sleep apnea. *J Appl Physiol* 2003;95(5):2023–2029.
15. Van de Heyning PH, Badr MS, Baskin JZ, et al. Implanted upper airway stimulation device for obstructive sleep apnea. *Laryngoscope* 2012;122(7): 1626–1633.