





International Journal of Surgery Case Reports

Available online 23 March 2021, 105823

In Press, Journal Pre-proof 

Case Report

Low morbidity high anterior neck approach for removal of a deep intraglossal foreign body: a case report

Anders W. Sideris ^{a, b}  , Leba M. Sarkis ^a, Matthew E. Lam ^{a, b}, Stuart G. Mackay ^{a, b, c}

Show more 

 Outline |  Share  Cite

<https://doi.org/10.1016/j.ijscr.2021.105823>

Under a Creative Commons license

Get rights and content

open access

Highlights

- The literature scarcely describes high anterior neck approaches to deep intra-glossal foreign bodies, tending to focus on transoral removal.
- This case describes a low morbidity anterior neck approach to removal of intraglossal foreign bodies that is utilised in insertion of bilateral hypoglossal nerve stimulators.
- The approach includes midline transcervical incision midway between the hyoid bone and inferior border of mandible, exposure and midline separation of mylohyoid muscles and midline dissection of geniohyoid muscles to expose genioglossi muscles.
- This approach carries low morbidity compared to transoral approaches despite traditional dogma mandating avoidance of open neck approaches.

Abstract

Introduction and importance

In the era of both new bilateral hypoglossal nerve stimulator and long-standing experience with Sistrunk's procedures, it is notable that the literature scarcely describes high anterior neck approaches, tending to focus on transoral removal of intra-glossal foreign bodies. Herein we describe a case of a low morbidity anterior approach for access to an intra-glossal foreign body and discuss the implications.

Case presentation

A morbidly obese 73 year old lady presented acutely after inadvertent ingestion of a sewing needle. Initial assessment demonstrated an intraglossal foreign body which subsequently migrated into the deep substance of the tongue. Endoscopic retrieval was attempted but was unsuccessful. A midline transcervical anterior neck incision was made, exposure and midline separation of mylohyoid, and midline dissection of geniohyoid muscles was performed to expose genioglossi muscles and the foreign body removed. The patient recovered well without complication.

Clinical discussion

This approach carries low morbidity compared to transoral approaches despite traditional dogma mandating avoidance of open neck approaches. Such approaches have recently been developed for implantation of bilateral hypoglossal nerve stimulators.

Conclusion

Otolaryngologists should consider midline transcervical approach to retrieve deep intra-glossal foreign bodies, particularly in scenarios where other options may not provide adequate access or may enhance intra-oral morbidity.

Keywords

Intra-glossal Foreign Body; Anterior Neck Approach; Otolaryngology Head and Neck Surgery; Ear Nose and Throat Surgery

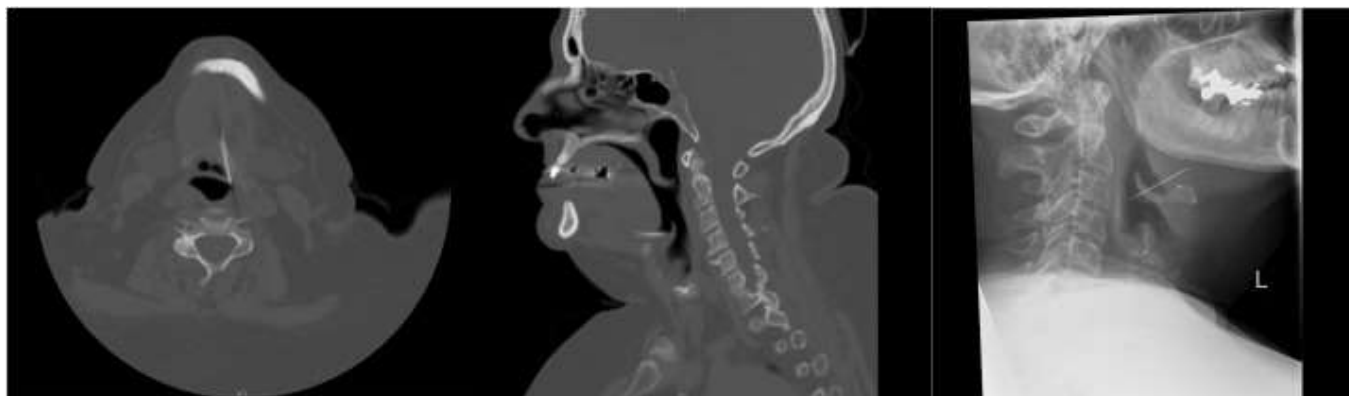1. Introduction

In the era of both new bilateral hypoglossal nerve stimulator ¹ and long standing experience with Sistrunk's procedures ², it is notable that the literature scarcely describes high anterior neck approaches, tending to focus on transoral removal of intra-glossal foreign bodies ³. Herein we describe a case of a low morbidity anterior approach for access to an intra-glossal foreign body and discuss the implications. This case report is presented compliant with the SCARE 2020 checklist ⁴.

Aim: To describe a low morbidity high anterior neck approach for access to an intra-glossal foreign body and discuss the implications.

2. Case Report

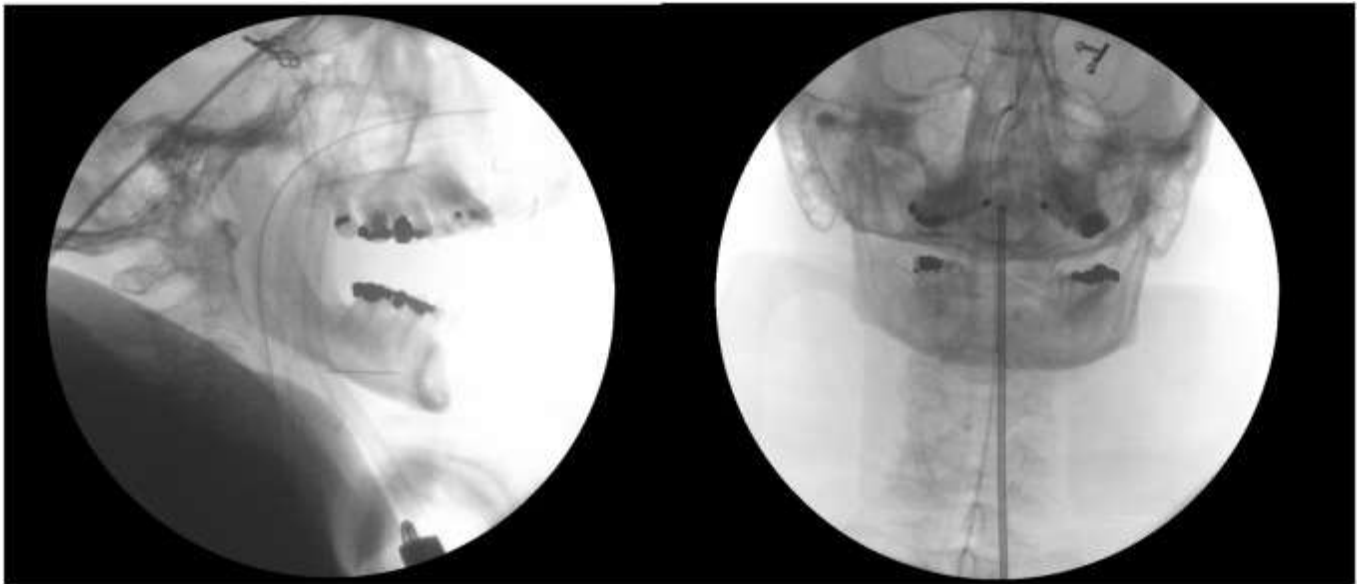
A morbidly obese (BMI 37.7) 73 year-old-lady with macroglossia and a history of type 2 diabetes mellitus, osteoarthritis, hypercholesterolaemia, hypothyroidism, chronic back pain self-presented acutely after inadvertent ingestion of a sewing needle. Initial imaging (CT and lateral airway x-ray) demonstrated the foreign body partially embedded in the substance of the tongue musculature with an intraluminal component amenable to endoscopic retrieval (Fig. 1). Between her initial presentation (Fig. 1) and access to an available operating room, the ingested foreign body had migrated significantly deeper into tongue substance (Fig. 2).



Download : [Download high-res image \(264KB\)](#)

Download : [Download full-size image](#)

Fig. 1. Preoperative imaging of the neck (CT and lateral airway x-ray) demonstrated foreign body partially embedded in the substance of the tongue musculature with an intraluminal component amenable to endoscopic retrieval.



Download : [Download high-res image \(396KB\)](#)

Download : [Download full-size image](#)

Fig. 2. Intraoperative image intensifier x-ray of the neck (lateral and AP) demonstrated complete foreign body migration into substance of the tongue.

The operative team (consultant otolaryngologist and senior otolaryngology registrar) investigated transoral approaches under general anaesthesia (total intravenous anaesthesia [propofol, remifentanyl]). These included utilisation of flexible nasendoscopy, rigid microlaryngoscopy, direct palpation, Boyle-Davis gag introduction and multiple operator techniques. None of these access points were able to identify a foreign body or aid in execution of appropriate retrieval. Image intensifier was employed and the foreign body identified deep in tongue musculature adjacent to the midline (Fig. 2).

A midline transcervical incision midway between the hyoid bone and inferior border of mandible exposed the mylohyoid muscles, which were separated in the midline to find the underlying thick geniohyoid muscles. Midline dissection allowed visualisation of both genioglossi muscle and the foreign body was identified paramedian immediately inferior to the edge of the left genioglossus. Such an approach has recently been developed for implantation of bilateral hypoglossal nerve stimulators ^{1,5}.

After foreign body removal and washout, layered re-approximation with 4-0 undyed Vicryl and skin closure with 4-0 subcuticular Monocryl was performed.

The patient recovered well from surgery with no neck pain, but did have minor lower lip bruising and oral tongue numbness. She was discharged 16 hours later from hospital, on prophylactic oral

antibiotics tolerating soft diet. Follow up one week later demonstrated a well healed neck wound and complete symptomatic recovery.

3. Discussion

Although this observation reports a single case only, the authors are of the opinion that the morbidity of multiple transoral attempts at identification and retrieval was greater than that of a simple 5 cm anterior neck incision. Lip bruising, risk of dental injury, floor of mouth trauma (delivering the tongue through the oral commissure), finger manipulation of the tongue and introduction of multiple scopes and instrumentation all carry risk. Yet traditional dogma mandates avoiding open neck approaches despite ease of access through known midline musculature in the anterior upper neck. Such dogma may be the result of anchoring or confirmation bias, based on preconceptions about described transcervical approaches to the tongue⁶. Potential risk to important neurovascular structures (e.g. hypoglossal nerves as they enter the genioglossi) can be reduced by remaining strictly midline and maintaining awareness of the position of the mandible and hyoid bones.

The authors urge readers to consider midline transcervical approach to retrieve deep intra-glossal foreign bodies, particularly in scenarios where other options may not provide adequate access or may enhance intra-oral morbidity.

Declaration of Competing Interest

There are no financial or other conflicts of interest to declare.

Sources of funding

No funding was sought or gained for this study.

Ethical Approval

Ethics approval not applicable. Appropriate patient consent gained.

Consent

Written informed consent was obtained from the patient for publication of this case report and accompanying images. A copy of the written consent is available for review by the Editor-in-Chief of this journal on request

Author contribution

Anders Sideris: Writing of manuscript, clinical care of patient

Leba Sarkis: Writing of manuscript, clinical care of patient

Matthew Lam: Writing of manuscript, clinical care of patient

Stuart Mackay: Writing of manuscript, consultant Otolaryngologist responsible for care of patient

All authors: Approval of final manuscript.

Registration of Research Studies

Not applicable

Guarantor

Prof Stuart Mackay, Dr Anders Sideris

Provenance and Peer Review

Not commissioned, externally peer reviewed.

[Recommended articles](#)

[Citing articles \(0\)](#)

References

- [1] P.R. Eastwood, M. Barnes, S.G. MacKay, *et al.*
Bilateral hypoglossal nerve stimulation for treatment of adult obstructive sleep apnoea
Eur Respir J., 55 (1) (2020)
[Google Scholar](#)
- [2] WE Sistrunk
THE SURGICAL TREATMENT OF CYSTS OF THE THYROGLOSSAL TRACT
Ann Surg., 71 (2) (1920), pp. 121-122
122
[CrossRef](#) [Google Scholar](#)
- [3] S Johari, KY Chong
Intraglossal impaction of ingested fish bones: a case series
Ear Nose Throat J., 89 (8) (2010), pp. 364-368
[View Record in Scopus](#) [Google Scholar](#)
- [4] R.A. Agha, T. Franchi, C. Sohrabi, G. Mathew, A. Kerwan
The SCARE 2020 Guideline: Updating Consensus Surgical CAse REport (SCARE) Guidelines

Int J Surg., 84 (2020), pp. 226-230

Article  Download PDF View Record in Scopus Google Scholar

- [5] R. Lewis, B. Pételle, M.C. Campbell, *et al.*
Implantation of the nyxoah bilateral hypoglossal nerve stimulator for obstructive sleep apnea

Laryngoscope Investig Otolaryngol., 4 (6) (2019), pp. 703-707

CrossRef View Record in Scopus Google Scholar

- [6] F. Chabolle, I. Wagner, M.B. Blumen, C. Séquert, B. Fleury, T. De Dieuleveult
Tongue Base Reduction With Hyoepiglottoplasty: A Treatment for Severe Obstructive Sleep Apnea

The Laryngoscope, 109 (8) (1999), pp. 1273-1280

View Record in Scopus Google Scholar

[View Abstract](#)

© 2021 Published by Elsevier Ltd on behalf of IJS Publishing Group Ltd.



[About ScienceDirect](#)

[Remote access](#)

[Shopping cart](#)

[Advertise](#)

[Contact and support](#)

[Terms and conditions](#)

[Privacy policy](#)

We use cookies to help provide and enhance our service and tailor content and ads. By continuing you agree to the **use of cookies**.

Copyright © 2021 Elsevier B.V. or its licensors or contributors. ScienceDirect® is a registered trademark of Elsevier B.V.

ScienceDirect® is a registered trademark of Elsevier B.V.

 RELX™

FEEDBACK 